

## BRIEF REPORT

## Evidence of MEN-2 in the Original Description of Classic Pheochromocytoma

Hartmut P.H. Neumann, M.D., Alexander Vortmeyer, M.D., Dieter Schmidt, M.D., Martin Werner, M.D., Zoran Erlic, M.D., Alberto Cascon, Ph.D., Birke Bausch, M.D., Andrzej Januszewicz, M.D., and Charis Eng, M.D., Ph.D.

## SUMMARY

The first description of pheochromocytoma in 1886 has been attributed to Felix Fränkel, who described an 18-year-old woman with bilateral adrenal “sarcoma and angio-sarcoma.” We reviewed the publication and then approached and assessed relatives of the patient to update the findings with the use of current technology. In-depth review revealed that the histopathological findings were consistent with pheochromocytoma. Because the proband was young and had bilateral disease at diagnosis, we hypothesized that she had an inherited condition. The presence of germ-line *RET* mutations in four living relatives demonstrates that the original patient and her family had multiple endocrine neoplasia type 2 and provides molecular evidence that she had pheochromocytoma.

THE FIRST DESCRIPTION OF ANY SPECIFIC CONDITION IS ALWAYS DIFFICULT to establish. The standard textbook on pheochromocytoma (*Clinical and Experimental Pheochromocytoma*, by William M. Manger and Ray Gifford) and a keynote address at the First International Symposium on Pheochromocytoma honored Felix Fränkel as the author of the first description of the condition.<sup>1,2</sup> Fränkel’s article,<sup>3</sup> published in 1886, described an 18-year-old woman named Minna Roll, a resident of Wittenweier (near the country town of Lahr) who had died in 1884. She was treated and died at the University Hospital of Freiburg. At autopsy, bilateral adrenal tumors were found. The pathologists who reported the autopsy findings, Drs. Max Schottelius and Rudolf Maier, diagnosed sarcoma for one tumor and angiosarcoma for the other. Fränkel’s report included his interpretation that the patient had a generalized vasoactive disease, but the term pheochromocytoma was not used. Written in German and spanning 20 pages, the article was translated into English as a Classic in Oncology in 1984.<sup>4</sup>

We used a multidisciplinary approach to reconsider Fränkel’s report, with two objectives. First, we questioned whether the interpretation of the report as describing pheochromocytoma was correct. Second, on the basis of Roll’s young age at diagnosis and her bilateral tumors, we addressed the hypothesis that she had an inherited disorder.<sup>5</sup> We considered differential diagnoses of von Hippel–Lindau disease caused by mutations in the *VHL* gene, multiple endocrine neoplasia type 2 (MEN-2) caused by *RET* mutations, and the pheochromocytoma–paraganglioma syndromes caused by mutations in the genes for succinate dehydrogenase subunits B, C, and D (*SDHB*, *SDHC*, and *SDHD*). We reasoned that if gene-based proof could be obtained, it would elucidate the mystery of the proband’s disease and validate the correct histopathological interpretation.

From the Departments of Nephrology (H.P.H.N., Z.E., A.C., B.B.), Ophthalmology (D.S.), and Pathology (M.W.), University of Freiburg Medical Center, Freiburg im Breisgau, Germany; the National Institute of Neurological Disorders and Stroke and Laboratory of Pathology, National Cancer Institute, Bethesda, MD (A.V.); the Department of Endocrinology, University of Padua School of Medicine, Padua, Italy (Z.E.); Hereditary Endocrine Cancer Group, Centro Nacional de Investigaciones Oncológicas, Madrid (A.C.); the Institute of Cardiology, Warsaw, Poland (A.J.); and the Genomic Medicine Institute, Lerner Research Institute, and Taussig Cancer Center, Cleveland Clinic Foundation, Cleveland (C.E.). Address reprint requests to Dr. Neumann at Medizinische Universitätsklinik, Hugstetter Straße 55, D 79106 Freiburg, Germany, or at hartmut.neumann@uniklinik-freiburg.de.

N Engl J Med 2007;357:1311-5.

Copyright © 2007 Massachusetts Medical Society.

## METHODS

## REVIEW OF THE ORIGINAL REPORT

We initially reviewed Fränkel's original article in the context of our group's involvement with studies of pheochromocytoma and paraganglioma for 23 years, working with patients and considering the background of families and potential susceptibility genes.<sup>5-9</sup> We contacted the archives of the Departments of Medicine and of the Institute of Pathology of the University of Freiburg, but we were unable to locate documents, tissue samples, or histological slides for the proband. We then contacted the university library and found the autopsy book from 1884, which contained the report on the proband.

## CONTACTING THE FAMILY

We contacted the church office of the village of Wittenweier and received the names of the parents and brothers of the proband. Having seemingly collected the maximum available information, we used the age (18 years), the tumor number (two), the tumor location (adrenals), and the geographic location (in the vicinity of Lahr) as data to input into the European-American Pheochromocytoma Registry (EAPR) to attempt to find possible relatives and determine whether the proband might have had a heritable pheochromocytoma disorder.

In November 2006, we searched the telephone directory of Wittenweier, found 20 entries with the proband's family name, and wrote to these identified persons on December 5, 2006. Four families responded. We visited these putative relatives on December 28, 2006. After interviews with these persons, we were directed to the address of one living relative who was potentially affected by pheochromocytoma. There was another branch of the Roll family living in the vicinity of Hamburg, but addresses were unknown. Again, we used the telephone directory. We found 54 entries for the family name in the Hamburg region and wrote to the potential relatives. By the end of January 2007, we had received replies from two additional relatives. Two family meetings were held to exchange specific information, including the family pedigree. We informed the entire family by letter and interview that they might be identifiable if the findings were published. All family members in our report provided written informed consent to participate in the study. All subjects who underwent genetic analyses provided written consent.

## GENETIC ANALYSES

We extracted genomic DNA from peripheral blood donated by the proband's living affected relatives. Mutation analysis for the pheochromocytoma-susceptibility genes *VHL*, *RET*, *SDHB*, and *SDHD* were performed as described previously.<sup>5</sup> The study was approved by the ethics committee at the University Clinics of Freiburg.

## RESULTS

## CLINICAL COURSE AND AUTOPSY REPORT

The proband presented in 1884 with the classic signs of malignant hypertension and died 10 days after admission to the hospital. On autopsy, bilateral adrenal tumors were found. A fist-sized left adrenal tumor showed numerous vessels or blood spaces, which had no wall and directly bordered on the cell masses of the tumor. Large cells with occasional large nuclei were observed within the tumor, which contained light-yellow to brown pigment. There were giant cells with fine granular cytoplasm and several large nuclei, each of which had one to three small nucleoli. A right adrenal tumor, which was the size of a hazelnut, was surrounded by tubular-shaped adrenal gland tissue. Tumor cells were similar in form to normal adrenal medulla. In the center of the tumor, spindle cells predominated. (See details in the accompanying box and in the Supplementary Appendix, which is available with the full text of this article at [www.nejm.org](http://www.nejm.org).)

## CLINICAL FEATURES AND PHENOTYPIC DATA

A total of 90 patients with bilateral adrenal pheochromocytomas were registered in the EAPR at the end of 2006. Among these patients, the frequencies of germ-line mutations were as follows: *VHL*, 47%; *RET*, 22%; neurofibromatosis 1 (*NF1*), 6%; and *SDHD*, 2%. No registry patients with bilateral adrenal pheochromocytomas had *SDHC* or *SDHB* mutations.

Of all the patients listed in the EAPR, 120 had been 18 years of age or younger at the time of diagnosis. Among these patients, the proportions with germ-line mutations of the various genes considered were as follows: *VHL*, 60%; *SDHD*, 9%; *SDHB*, 5%; *NF1*, 3%; and *RET*, 1%. Of the 36 patients who were living in the vicinity of Lahr, 18 had mutations in the *VHL* gene, 1 in the *RET* gene, and 1 in the *SDHB* gene.

On the basis of registry data and statistical probability, the proband, who had early-onset dis-

**The Patient and Her Disease (translated and summarized from the Fränkel report)**

The patient was born in 1865 and lived in Wittenweier near Lahr in the Black Forest region, 40 km north of Freiburg. Her parents and six brothers were healthy. Her illness began in the winter of 1883, when she was 18 years of age. It was characterized by three attacks of sudden-onset palpitations, anxiety, dizziness, headache, vomiting, constipation, and increasing weakness. She was hospitalized on December 11, 1884, and died 10 days later. When she presented, she was noted to be fairly malnourished, pale, with "agitated heart action and strong pulse," epigastric pulsations, photophobia, and mydriatic pupils. Urinalysis revealed proteinuria, casts, and microhematuria. Retinoscopy revealed papilledema, yellow-white infiltrations, whitish stippling, multiple hemorrhages, and edema of the macula. During her inpatient stay, she had paroxysmal tachycardia (up to 180 beats per minute), sweating attacks, headaches, vomiting, visual deterioration, arrhythmia, nosebleeds, anxiety, and, in the end, severe chest pains.

**Autopsy Report**

The translation of Rudolf Maier's handwritten autopsy report, to the best of our interpretation, is available in the Supplementary Appendix. In brief, the salient points include a young woman with autopsy signs of prolonged malignant hypertension, including extensive hemorrhage of multiple organs, a thyroid goiter, a fist-sized tumor above the upper pole of the left kidney, and a small nodule in the right adrenal gland.

**Histologic Features of the Adrenal Tumors**

Microscopical examination revealed that the adrenal tumors were vascular or apparently vascular. The description of the right adrenal tumor is telling: the tumor was surrounded by an adrenal substance in a tube-shaped arrangement and contained large cells rich in protoplasm with one or more large nuclei thoroughly resembling adrenal medullary cells. The nuclei were twice to three times the size of those in normal adrenal medullary cells. Cell arrangements recalled the form of complexes in the normal medulla but often lost the typical form closer to the center of the tumor. Here, spindle cells predominated. Along the boundary between tumor and normal tissue, very circumscribed small-cell infiltration foci in the vessels were shown, which in other parts had partially or completely transformed into connective tissue. At individual places, such accumulations made the impression of small fibroma nodules. (Further details can be found in the Supplementary Appendix.)

**Family History**

The patient's niece (Subject III:1 in Fig. 1) underwent three operations for pheochromocytoma between the ages of 36 and 67 years and died after the last operation in 1970 from metastasis. Her first nephew, Subject III:2, underwent an operation for pheochromocytoma at the age of 44 years. After his death in 1952 after an accident, a contralateral pheochromocytoma was revealed on autopsy. Her second nephew, Subject III:3, underwent surgery for pheochromocytoma as well and died at the age of 41 years. The son of Subject III:2, Subject IV:1, received the diagnosis of bilateral pheochromocytomas and medullary thyroid carcinoma during a workup for a prostate problem. He underwent surgery for these conditions in 2003 in Hamburg. On the basis of genetic diagnosis, Subject IV:2 underwent surgery for medullary thyroid carcinoma in 2003 but had no pheochromocytoma. His niece, Subject V:1, whose condition was also diagnosed genetically, underwent surgery for unilateral pheochromocytoma and medullary thyroid carcinoma in 2004.

Other interesting family history included descendants of another brother of the proband, Subject II:7, who died at the age of 79 years. His daughter, Subject III:11, died at the age of 47 years after undergoing cholecystectomy because of an "adrenal cortical complication," as reported to the family. This woman's son, Subject IV:14, who was registered in the European-American Pheochromocytoma Registry, received the diagnosis of a left pheochromocytoma in 1972 at the age of 27 years and of a right pheochromocytoma at the age of 32 years; both tumors were removed. At the age of 39 years, he underwent thyroid surgery, and histologic analysis revealed a medullary thyroid carcinoma.

ease and was a resident of the Lahr area, probably had a mutation in the *VHL* gene.

**CLINICAL AND GENETIC FEATURES OF FAMILY MEMBERS**

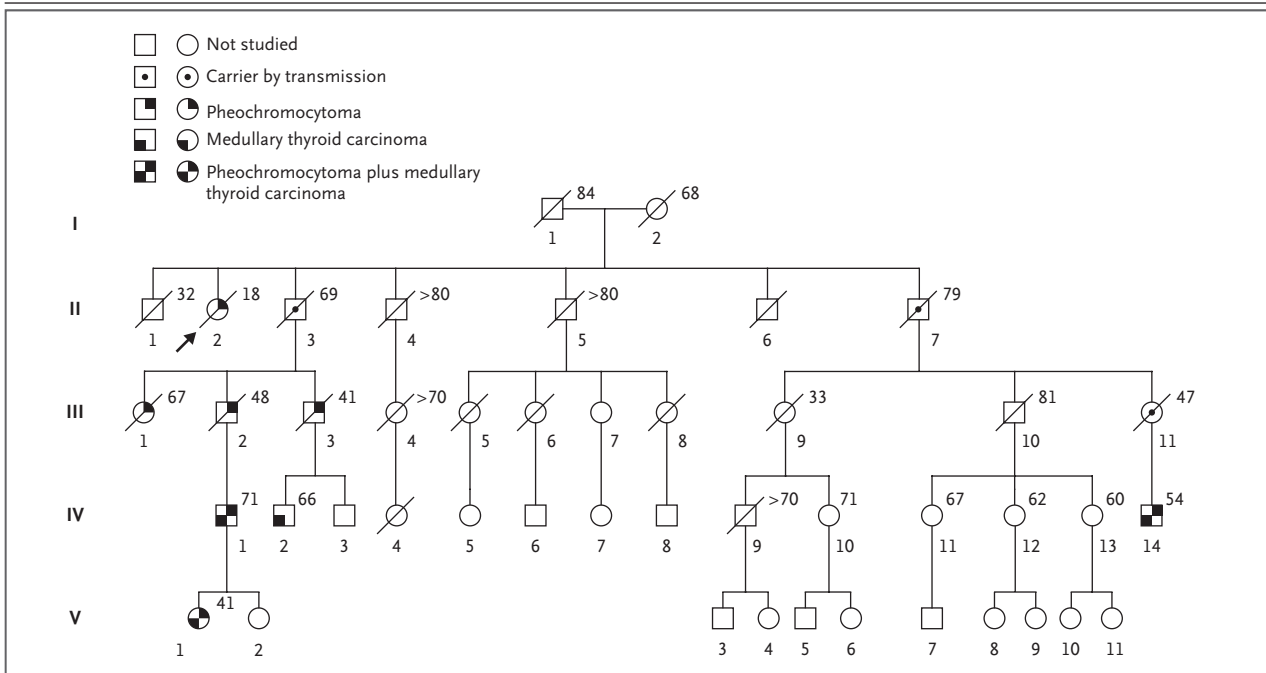
On the basis of tracing the family's lineage and information provided by responding relatives, we constructed a pedigree (Fig. 1). In brief, six descendants had evidence of the development of pheochromocytoma between the ages of 36 and 44 years, and four had medullary thyroid carcinoma.

We were able to obtain genomic DNA from the peripheral lymphocytes of four living affected relatives of the proband. One grandnephew's DNA had already been analyzed in 1995 as part of our registry efforts. He had been found to have the

germ-line *RET* mutation TGC→TGG (Cys634Trp) (Fig. 2). This family-specific *RET* mutation was found in three other relatives whose DNA had been tested in another laboratory in the past; we confirmed this finding in 2007.

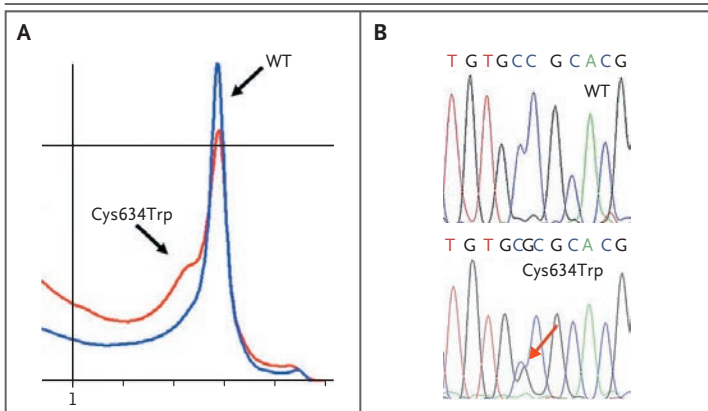
**DISCUSSION**

Minna Roll, a previously healthy young woman, presented to the University Hospital of Freiburg at the end of 1884 and died 10 days after admission from what appeared by description to be the classic signs of pheochromocytoma. These signs included sudden paroxysms of palpitations, dizziness, headache, vomiting, weakness, constipation, and reduction of visual acuity.<sup>10</sup> Only indirect signs of hypertension were described (e.g., "ten-



**Figure 1. Pedigree of Proband's Extended Family.**

This pedigree was constructed after interviews with three family members (Subjects IV:11, IV:1, and IV:2) of the proband (Subject II:2, arrow). Only family members who consented to participate in our study and who specifically acknowledged the likelihood that they might be identifiable are depicted. The number next to each symbol shows the family member's age in 2007 or at the time of death. Squares denote male family members, circles female family members, and symbols with slashes deceased family members.



**Figure 2. Germ-Line RET Cys634Trp Mutation in the Grandnephew of the Proband.**

Panel A shows the DHPLC pattern of wild-type (WT) and mutant (Cys634Trp) genes in the proband's grandnephew (Subject IV:14 in Fig. 1). Panel B is the sequencing chromatogram showing the WT sequence and the heterozygous mutation (arrow).

sion of the arteries,” epigastric pulsation, and epistaxis). Her retinal examination was also classic for stage IV hypertensive retinopathy.<sup>11</sup> At a time when pheochromocytoma was not yet described,

Felix Fränkel and colleagues reported what they called bilateral adrenal sarcoma and angiosarcoma. Remarkably, Fränkel considered that abnormal quantities of a substance normally present in the blood might be released in an unregulated manner to the circulation, resulting in “irritation” of the blood vessels and parenchyma of other organs. Thus, he postulated the endocrine nature and function of the adrenal medulla. The autopsy description of the smaller nodule within the right adrenal medulla is helpful and clearly delineates the microscopical features of a nonmalignant pheochromocytoma.

In an interesting coincidence, Müller's fixative was used in the preparation of the specimen. This fixative contains chromate as an essential component. When exposed to chromate, the tumor cells showed a distinct staining, which was later described by Ludwig Pick, a pathologist from Berlin, as “chromate brown” or “phäo [pheo] chrom.” To the best of our knowledge, Pick was the first to introduce the term pheochromocytoma in 1912.<sup>12</sup> Fränkel's article not only provided the first detailed clinical and histopathological

description of pheochromocytoma but also recognized that the two tumors were of the same type. Therefore, the detailed histopathological description of a previously unknown type of neoplasm, as well as the astute remarks made by Fränkel, permit the conclusion that the patient did indeed present with bilateral pheochromocytoma.<sup>13</sup>

The proband was only 18 years old at the time of her presentation with bilateral pheochromocytoma. Although Fränkel and colleagues never considered the cause or the implications of an inherited predisposition, the proband had two clinical “red flags” that pointed to an inherited condition: her young age at diagnosis and bilateral disease in paired organs. The differential diagnosis comprises von Hippel–Lindau disease, MEN-2, and the pheochromocytoma–paraganglioma syndrome types 1 and 4. In addition, the proband’s residence in the Black Forest region initially pointed to von Hippel–Lindau disease, given findings in families who were subsequently diagnosed with this condition in that region of Germany. However, to our surprise, the family-lineage tracing and pedigree construc-

tion revealed not only that four descendants had medullary thyroid carcinoma but also that four living affected family members had the germline Cys634Trp mutation in the *RET* gene, thus establishing the clinical and molecular diagnosis of MEN-2. It is unusual for pheochromocytoma to present before medullary thyroid carcinoma in MEN-2. It is interesting, therefore, to note that the gross autopsy describes a “goiter” in the proband’s thyroid, which was not histologically pursued. Given the medullary thyroid carcinoma and pheochromocytoma in this family and the *RET* Cys634Trp mutation, the proband had MEN-2.

Supported in part by a grant (70-3313-Ne 1) from the Deutsche Krebshilfe, a grant (NE 571/5-3) from the Deutsche Forschungsgemeinschaft, and a grant (LSHC-CT-2005-518200) from the European Union (all to Dr. Neumann); and grants (R01HD39058-01 and R01HD39058-01S1, to Dr. Eng) from the National Institutes of Health. Dr. Eng is a recipient of the Doris Duke Distinguished Clinical Scientist Award.

No potential conflict of interest relevant to this article was reported.

We thank members of the proband’s family for their assistance; Justus Schottelius, of Elmshorn, for information regarding Max Schottelius; and Kurt Wegener, of Ludwigshafen/Rhein, for his critical review of a draft of the manuscript.

#### REFERENCES

- Manger WM, Gifford RW. Clinical and experimental pheochromocytoma. London: Blackwell Science, 1996:5.
- Manger WM. An overview of pheochromocytoma: history, current concepts vagaries, and diagnostic challenges. *Ann N Y Acad Sci* 2006;1073:1-20.
- Fränkel F. Ein Fall von doppelseitigem, völlig latent verlaufenen Nebennierentumor und gleichzeitiger Nephritis mit Veränderungen am Circulationsapparat und Retinitis. *Arch Pathol Anat Physiol Klin Med* 1886;103:244-63.
- Classics in oncology: a case of bilateral completely latent adrenal tumor and concurrent nephritis with changes in the circulatory system and retinitis: Felix Fränkel, 1886. *CA Cancer J Clin* 1984;34:93-106.
- Neumann HP, Bausch B, McWhinney SR, et al. Germ-line mutations in nonsyndromic pheochromocytoma. *N Engl J Med* 2002;346:1459-66.
- Bausch B, Borozdin W, Neumann HPH. Clinical and genetic characteristics of patients with neurofibromatosis type 1 and pheochromocytoma. *N Engl J Med* 2006;354:2729-31.
- Bausch B, Boedeker CC, Berlis A, et al. Genetic and clinical investigation of pheochromocytoma: a 22-year experience, from Freiburg, Germany to international effort. *Ann N Y Acad Sci* 2006;1073:122-37.
- Neumann HP, Pawlu C, Peczkowska M, et al. Distinct clinical features of paraganglioma syndromes associated with SDHB and SDHD gene mutations. *JAMA* 2004;292:943-51. [Erratum, *JAMA* 2004;292:1686.]
- Schiavi F, Boedeker CC, Bausch B, et al. Predictors and prevalence of paraganglioma syndrome associated with mutations of the SDHC gene. *JAMA* 2005;294:2057-63. [Erratum, *JAMA* 2006;295:628.]
- Landsberg L, Young JB. Pheochromocytoma. In: Kasper DL, Braunwald E, Fauci AS, Hauser SL, Longo DL, Jameson JL, eds. *Harrison’s principles of internal medicine*. 16th ed. New York: McGraw-Hill, 2005:2148-52.
- Keith NM, Wagener HP, Barker NW. Some different types of essential hypertension: their course and prognosis. *Am J Med Sci* 1939;197:332-43.
- Pick L. Das Ganglioma embryonale sympathicum (Sympathoma embryonale). *Berl Klin Wschr* 1912;49:16-22.
- McNicol AM, Young WF, Kawashima A, Komminoth P, Tischler AS. Benign pheochromocytoma. In: DeLellis RA, Lloyd RV, Heitz PU, Eng C. *Pathology and genetics: tumours of endocrine organs*. Lyon, France: IARC Press, 2004:151-5.

Copyright © 2007 Massachusetts Medical Society.

#### COLLECTIONS OF ARTICLES ON THE JOURNAL’S WEB SITE

The Journal’s Web site ([www.nejm.org](http://www.nejm.org)) sorts published articles into more than 50 distinct clinical collections, which can be used as convenient entry points to clinical content. In each collection, articles are cited in reverse chronologic order, with the most recent first.