



Diagnosis and treatment of cardiac amyloidosis: a position statement of the ESC Working Group on Myocardial and Pericardial Diseases

Pablo Garcia-Pavia ^{1,2,3*}, **Claudio Rapezzi** ^{4,5}, **Yehuda Adler** ⁶, **Michael Arad** ⁷,
Cristina Basso ^{3,8,9}, **Antonio Brucato** ¹⁰, **Ivana Burazor** ¹¹,
Alida L.P. Caforio ^{3,12}, **Thibaud Damy** ^{3,13}, **Urs Eriksson** ¹⁴,
Marianna Fontana ¹⁵, **Julian D. Gillmore** ¹⁵, **Esther Gonzalez-Lopez** ^{1,3},
Martha Grogan ¹⁶, **Stephane Heymans** ^{17,18,19}, **Massimo Imazio** ²⁰,
Ingrid Kindermann ²¹, **Arnt V. Kristen** ^{22,23}, **Mathew S. Maurer** ²⁴,
Giampaolo Merlini ^{25,26}, **Antonis Pantazis** ²⁷, **Sabine Pankuweit** ²⁸,
Angelos G. Rigopoulos ²⁹, and **Ales Linhart** ³⁰

¹Heart Failure and Inherited Cardiac Diseases Unit, Department of Cardiology, Hospital Universitario Puerta de Hierro Majadahonda, CIBERCV, Manuel de Falla, 2, 28222 Madrid, Spain; ²Universidad Francisco de Vitoria (UFV), Pozuelo de Alarcon, Spain; ³European Reference Network for Rare, Low Prevalence and Complex Diseases of the Heart-ERN GUARD-Heart; ⁴Cardiologic Centre, University of Ferrara, Italy; ⁵Maria Cecilia Hospital, GVM Care & Research, Cotignola, Italy; ⁶Leviev Heart Centre, Chaim Sheba Medical Centre (affiliated to Tel Aviv University), Israel; ⁷Heart Failure Institute, Leviev Heart Centre, Sheba Hospital and Sackler School of Medicine, Tel Aviv University, Israel; ⁸Cardiovascular Pathology Unit, University Hospital, Padua, Italy; ⁹Department of Cardiac, Thoracic and Vascular Sciences and Public Health, University of Padua, Padua, Italy; ¹⁰Dipartimento di Scienze Biomediche e Cliniche, Università degli Studi di Milano, Ospedale Fatebenefratelli, Italy; ¹¹Belgrade University School of Medicine, Cardiology, Institute for Rehabilitation, Belgrade, Serbia; ¹²Cardiology, Department of Cardiac Thoracic Vascular Sciences and Public Health, University of Padova, Padova, Italy; ¹³French Referral Centre for Cardiac Amyloidosis, Amyloidosis Mondor Network, GRC Amyloid Research Institute, CHU Henri Mondor, Créteil, France; ¹⁴GZO—Zurich Regional Health Centre, Wetzikon & Cardioimmunology, Centre for Molecular Cardiology, University of Zurich, Switzerland; ¹⁵National Amyloidosis Centre, Division of Medicine, University College London, Royal Free Hospital, London, UK; ¹⁶Cardiac Amyloid Clinic, Division of Circulatory Failure, Department of Cardiovascular Diseases, Mayo Clinic, Rochester, MN, USA; ¹⁷Department of Cardiology, Maastricht University, CARIM School for Cardiovascular Diseases, Maastricht, Netherlands; ¹⁸Centre for Molecular and Vascular Biology, KU Leuven, Leuven, Belgium; ¹⁹ICIN-Netherlands Heart Institute, Holland Heart House, Utrecht, Netherlands; ²⁰Cardiovascular and Thoracic Department, University Cardiology, AOU Città della Salute e della Scienza di Torino, Torino, Italy; ²¹Department of Internal Medicine III (Cardiology, Angiology and Intensive Care), Saarland University Medical Centre, Saarland University, Homburg/Saar, Germany; ²²Department of Cardiology, University of Heidelberg, Germany; ²³Cardiovascular Centre Darmstadt, Heidelberg, Germany; ²⁴Cardiac Amyloidosis Program, Centre for Advanced Cardiac Care, Columbia University Irving Medical Centre, New York Presbyterian Hospital, New York, NY, USA; ²⁵Amyloidosis Research and Treatment Centre, Fondazione Istituto di Ricovero e Cura a Carattere Scientifico Policlinico San Matteo, Pavia, Italy; ²⁶Department of Molecular Medicine, University of Pavia, Italy; ²⁷Cardiomyopathy Service, Royal Brompton Hospital, London, UK; ²⁸Department Of Cardiology, Philipps-University Marburg, Marburg, Germany; ²⁹Mid-German Heart Centre, Department of Internal Medicine III, Division of Cardiology, Angiology and Intensive Medical Care, University Hospital Halle, Martin-Luther-University Halle-Wittenberg, Halle (Saale), Germany; and ³⁰2nd Department of Medicine, Department of Cardiovascular Medicine, First Faculty of Medicine, Charles University, General University Hospital, Prague, Czech Republic

Received 15 May 2020; revised 27 July 2020; editorial decision 12 January 2021; accepted 1 February 2021; online publish-ahead-of-print 7 April 2021

Abstract

Cardiac amyloidosis is a serious and progressive infiltrative disease that is caused by the deposition of amyloid fibrils at the cardiac level. It can be due to rare genetic variants in the hereditary forms or as a consequence of acquired conditions. Thanks to advances in imaging techniques and the possibility of achieving a non-invasive diagnosis, we now know that cardiac amyloidosis is a more frequent disease than traditionally considered. In this position paper the Working Group on Myocardial and Pericardial Disease proposes an invasive and non-invasive definition of cardiac amyloidosis, addresses clinical scenarios and situations to suspect the condition and proposes a diagnostic algorithm to aid diagnosis. Furthermore, we also review how to monitor and treat cardiac amyloidosis, in an attempt to bridge the gap between the latest advances in the field and clinical practice.

* Corresponding author. Tel: + 34 911917297, Email: pablogpavia@yahoo.es

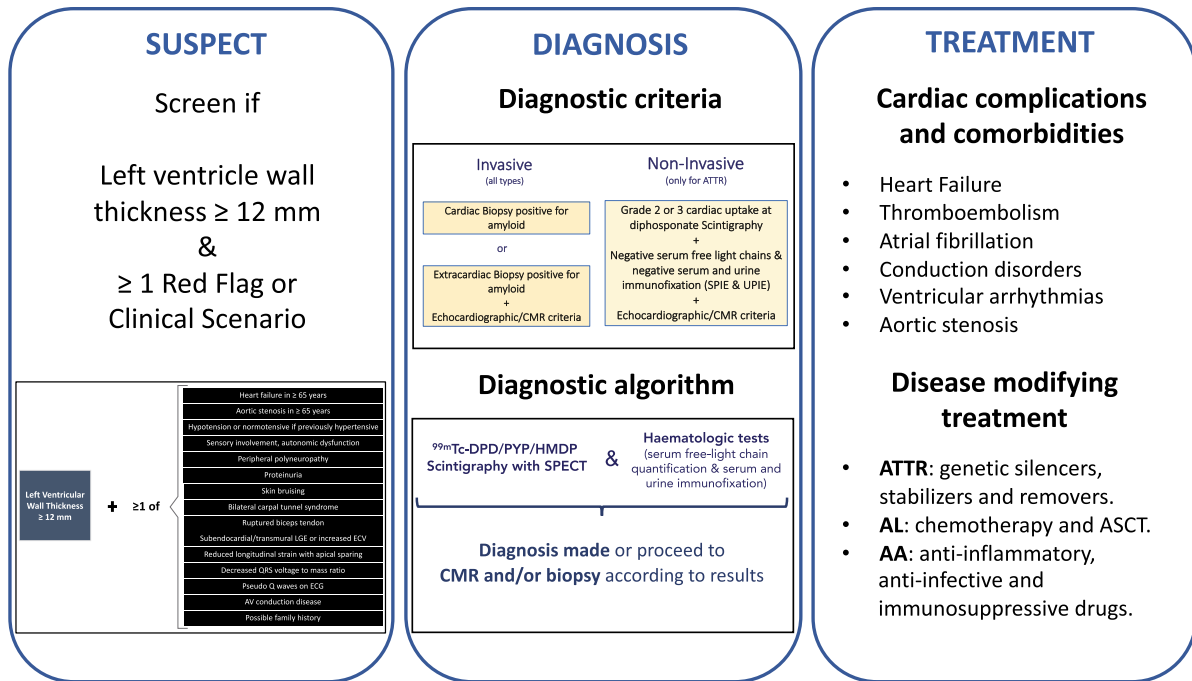
© European Society of Cardiology 2021

This article has been co-published with permission in *European Heart Journal* (published by Oxford University Press on behalf of European Society of Cardiology) and *European Journal of Heart Failure* (published by John Wiley & Sons Ltd on behalf of European Society of Cardiology) These articles are identical except for minor stylistic and spelling differences in keeping with each journal's style. Either citation can be used when citing this article.

Graphical Abstract

Cardiac amyloidosis

ESC Myocardial WG position paper



Cardiac amyloidosis

Keywords

Amyloidosis • Cardiac amyloidosis • Diagnosis • Treatment • AL • TTR • Transthyretin

Introduction

Cardiac amyloidosis is characterized by the extracellular deposition of mis-folded proteins in the heart with the pathognomonic histological property of green birefringence when viewed under cross polarized light after staining with Congo red.¹

Although considered a rare disease, recent data suggest that cardiac amyloidosis is underappreciated as a cause of common cardiac diseases or syndromes.² Recent advances in cardiac imaging, diagnostic strategies, and therapies have improved the recognition and treatment of cardiac amyloidosis.^{1,2}

The aim of this position paper by the European Society of Cardiology (ESC) Working Group on Myocardial and Pericardial Diseases is to help cardiologists and other physicians in recognizing, diagnosing, and treating patients with cardiac amyloidosis.

Definitions and classifications

Types of cardiac amyloidosis

While more than 30 proteins are known to be capable of aggregating as amyloid *in vivo*, only nine amyloidogenic proteins accumulate in the myocardium to cause significant cardiac disease.³

Nevertheless, some forms (AApoAI, AApoAII, AApoAIV, A β 2M, AFib, AGel) are very rare and cardiac amyloidosis secondary to chronic inflammatory and infectious diseases (AA), although still encountered, is now much less frequent. Accordingly, >98% of currently diagnosed cardiac amyloidosis results from fibrils composed of monoclonal immunoglobulin light chains (AL) or transthyretin (ATTR), either in its hereditary (ATTR_v) or acquired (ATTR_{wt}) form. Table 1 describes the main characteristics of each type of cardiac amyloidosis.

Definition of cardiac amyloidosis: diagnostic criteria

Cardiac amyloidosis is diagnosed when amyloid fibrils are found within cardiac tissue. Both invasive and non-invasive diagnostic criteria have been proposed. Invasive diagnostic criteria apply to all forms of cardiac amyloidosis whereas non-invasive criteria are accepted only for ATTR (Figure 1).

Invasive diagnostic criteria

Cardiac amyloidosis is confirmed when an endomyocardial biopsy demonstrates amyloid deposits after Congo red staining irrespective of the degree of left ventricular (LV) wall thickness. Identification of amyloid should be followed by classification of the amyloid fibril protein. Although the gold standard for defining the type of amyloid remains mass spectrometry, immunohistochemistry, or immunoelectron microscopy are routinely employed for amyloid typing in specialized centres.⁴

Diagnosis is also confirmed if amyloid deposits within an extracardiac biopsy are accompanied either by characteristic features of cardiac amyloidosis by echocardiography, in the absence of an alternative cause for increased LV wall thickness, or by characteristic features on cardiac magnetic resonance (CMR) (Table 2).

A recent multicentre study has proposed an echocardiographic score to facilitate echocardiographic diagnosis of AL or ATTR amyloidosis in the presence of increased LV wall thickness.⁵ Although not yet externally validated, a score ≥ 8 points in the presence of LV wall thickness ≥ 12 mm in combination with amyloid deposits in an extracardiac biopsy could also be considered diagnostic of cardiac amyloidosis (Table 2).

Non-invasive diagnostic criteria

Cardiac ATTR amyloidosis can be diagnosed in the absence of histology in the setting of typical echocardiographic/CMR findings when ^{99m}Tc-pyrophosphate (PYP), ^{99m}Tc-3,3-diphosphono-1,2-propanodicarboxylic acid (DPD) or ^{99m}Tc-hydroxymethylene diphosphonate (HMDP) scintigraphy shows Grade 2 or 3 myocardial uptake of radiotracer (Figure 2) and clonal dyscrasia is excluded by all the following tests: serum free light chain (FLC) assay, serum (SPIE), and urine (UPIE) protein electrophoresis with immunofixation.⁶ The combination of SPIE, UPIE, and quantification of serum FLC has a sensitivity of 99% for identifying abnormal pro-amyloidotic precursor in AL amyloidosis.⁷ It is important to stress that serum and urine protein electrophoresis should always be performed with immunofixation to increase the sensitivity of the assays for detecting monoclonal proteins (Table 3). Interpretation of low-level monoclonal protein or mild elevations in the kappa: lambda ratio (FLC ratio) could be challenging. These findings can be encountered in patients with chronic kidney disease (CKD) or with monoclonal gammopathy of undetermined significance (MGUS). In patients with CKD, as the glomerular filtration rate (GFR) declines, the renal clearance of polyclonal FLC decreases and serum concentrations rise.⁸ The FLC ratio also varies as the GFR declines, but this depends on the FLC assay available [Freelite assay (Binding Site) or N Latex assay (Siemens)].⁸ With the N Latex assay, the FLC ratio decreases as GFR declines but no reference range in CKD has yet been proposed. In contrast, with the most frequently used Freelite assay, FLC ratio increases as GFR declines

and a ratio of 0.37–3.1 has been proposed to be normal in patients with CKD. No reference values are available according to the severity of CKD, but in patients with moderate CKD (estimated GFR < 45 mL/min/1.73 m² by CKD-EPI formula) in the setting of a normal SPIE/UPIE, a FLC ratio up to 2.0 (or 3.1 if in dialysis) can typically be considered normal (Table 3). Otherwise, consultation with a haematologist is warranted.

In the absence of a detectable monoclonal protein and an abnormal serum FLC ratio, the specificity of Grade 2 or 3 bone scintigraphy for cardiac ATTR when the disease is suspected has been proposed to be almost 100%.⁶ Please note, however, that scintigraphy should always include single photon emission computed tomography to confirm that cardiac uptake corresponds to myocardium uptake and not from cardiac chambers (Table 4). Nevertheless, recent reports have shown that rare situations can also lead to positive cardiac uptake.⁹ These situations should always be considered when interpreting scintigraphy results (Table 4).

Once cardiac ATTR amyloidosis is confirmed, genetic counselling and testing should be performed to assess for the presence of *TTR* mutations in order to differentiate between ATTRwt and ATTRv. Genetic testing should be performed even in elderly patients, as a significant number can have *TTR* mutations.¹⁰

Essential concepts

- Although nine types of cardiac amyloidosis are known, AL and ATTR currently account for the vast majority of cardiac amyloidosis.
- Both invasive and non-invasive diagnostic criteria are accepted to diagnose cardiac amyloidosis. While invasive diagnostic criteria apply to all forms of cardiac amyloidosis, non-invasive criteria are accepted only for ATTR.

Diagnosis of cardiac amyloidosis

Diagnosis of cardiac amyloidosis includes two critical phases: (i) *suspicious phase* and (ii) *definite diagnosis phase*. The latter phase also includes appropriate typing of the amyloid, which is critical to guide specific treatment.

When to suspect cardiac amyloidosis

Red flags

Cardiac amyloidosis typically appears within a constellation of extracardiac signs and symptoms that are extremely useful to suspect the disease in the presence of compatible cardiac imaging findings. These signs and symptoms are termed 'red flags' and include proteinuria (even mild), macroglossia, skin bruises, and carpal tunnel syndrome, among others (Table 5). There are also various red flags at the cardiac level, such as heart failure [including disproportionately high N-terminal pro-B-type natriuretic peptide (NT-proBNP)] that appears to be in disproportion to 'objective' findings on echocardiogram, 'unexplained' right heart failure in the presence of ostensibly 'normal' ventricular and valvular function, or 'idiopathic' pericardial effusion. Persistent troponin elevation, disproportionately low QRS voltage or early conduction system disease are also signs that could evoke cardiac amyloidosis (Table 5).

Table 1 Amyloidosis subtypes that affect the heart

Amyloidosis type	Protein	Hereditary	Frequency of heart involvement	Median survival from diagnosis (months)	Usual extracardiac signs
AL	Immunoglobulin light chain	No	70%	24 6 (if HF at diagnosis and not treated)	Nephropathy, proteinuria, autonomic dysfunction, polyneuropathy, macroglossia, spontaneous bruising, liver involvement
ATTRwt	Transthyretin	No	100%	57	CTS, LSS, ruptured biceps tendon
ATTRv	Transthyretin	Yes	30–100% Depending on the mutation	31 (Val142Ile) 69 (non-Val142Ile)	Polyneuropathy, orthostatic hypotension, vitreous opacities, gastrointestinal problems
AA	Serum amyloid A	No	5%	133	Renal impairment (95%), proteinuria, hepatomegaly, gastrointestinal problems
AFib	Fibrinogen α	Yes	Rare	180	Renal impairment, proteinuria
AApoAI	Apolipoprotein A-I	Yes	Rare Depending on the mutation	No data. Probably >120	Primarily renal impairment, proteinuria, hepatosplenomegaly, adrenal insufficiency, dysphonia due to laryngeal involvement
AApoAII	Apolipoprotein A-II	Yes	Rare Depending on the mutation	No data	Primarily renal impairment, proteinuria
AApoAIV	Apolipoprotein A-IV	No	Unknown	79	Primarily renal impairment
A β 2M	β 2-microglobulin	No	80%	No data	Long-term dialysis, CTS, joint problems
AGel	Gelsolin	Yes	5% Primarily conduction disease	Near normal life expectancy	Corneal lattice dystrophy, cutis laxa, drooping eyelids, paresthesia, proteinuria (rare)

AA, serum amyloid A amyloidosis; AApoAI, apolipoprotein AI amyloidosis; AApoAII, apolipoprotein AII amyloidosis; AApoAIV, apolipoprotein A-IV amyloidosis; A β 2M, β 2-microglobulin amyloidosis; AFib, fibrinogen amyloidosis; AGel, gelsolin amyloidosis; AL, light-chain amyloidosis; ATTRwt, wild-type transthyretin amyloidosis; ATTRv, hereditary transthyretin amyloidosis; ATTRwt, wild-type transthyretin amyloidosis; CTS, carpal tunnel syndrome; HF, heart failure; LSS, lumbar spinal stenosis.

Diagnosis of Cardiac Amyloidosis

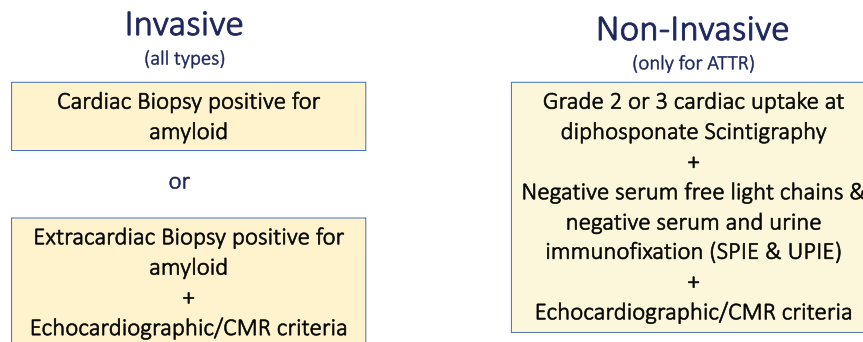


Figure 1 Invasive and non-invasive diagnosis of cardiac amyloidosis. ATTR, transthyretin amyloidosis; CMR, cardiac magnetic resonance; SPIE, serum protein electrophoresis with immunofixation; UPIE, urine protein electrophoresis with immunofixation.

Table 2 Echocardiographic and cardiac magnetic resonance criteria for non-invasive and invasive (with extracardiac biopsy-proven amyloidosis) diagnosis of cardiac amyloidosis

Echocardiography

Unexplained LV thickness (≥ 12 mm) plus 1 or 2:

1. Characteristic echocardiography findings (≥ 2 of a, b, and c have to be present):
 - a. Grade 2 or worse diastolic dysfunction
 - b. Reduced tissue Doppler s' , e' , and a' waves velocities (< 5 cm/s)
 - c. Decreased global longitudinal LV strain (absolute value $< -15\%$).
2. Multiparametric echocardiographic score ≥ 8 points:
 - a. Relative LV wall thickness (IVS+PWT)/LVEDD > 0.6
3 points
 - b. Doppler E wave/ e' wave velocities > 11
1 point
 - c. TAPSE ≤ 19 mm
2 points
 - d. LV global longitudinal strain absolute value $\leq -13\%$
1 point
 - e. Systolic longitudinal strain apex to base ratio > 2.9
3 points

CMR

Characteristic CMR findings (a and b have to be present):

- a. Diffuse subendocardial or transmural LGE
- b. Abnormal gadolinium kinetics^a
- c. ECV $\geq 0.40\%$ (strongly supportive, but not essential/diagnostic)

CMR, cardiac magnetic resonance; ECV, extracellular volume; IVS, interventricular septum; LGE, late gadolinium enhancement; LV, left ventricular; LVEDD, left ventricular end-diastolic diameter; PWT, posterior wall thickness; TAPSE, tricuspid annular plane systolic excursion.

^aAbnormal gadolinium kinetics: myocardial nulling preceding or coinciding with the blood pool.

Clinical scenarios

In addition to cardiac and extracardiac findings fostering the suspicion, there are several clinical situations in which cardiac amyloidosis should always be considered.

Cardiac disease in the presence of a typical systemic condition such as plasma cell dyscrasia, nephrotic syndrome, peripheral neuropathy, or a chronic systemic inflammatory condition should prompt consideration of amyloidosis, particularly if compatible cardiac imaging findings are present.

Increased wall thickness in a non-dilated left ventricle is a prominent characteristic of cardiac amyloidosis and should trigger further evaluation when found in elderly patients with common cardiac syndromes like heart failure with preserved ejection fraction, hypertrophic cardiomyopathy, or severe aortic stenosis, particularly among those undergoing transcatheter aortic valve replacement.^{11–13}

As ATTR has been found in a significant number of patients (up to 7–19%) in the abovementioned clinical scenarios, and with the possibility of non-invasive diagnosis, we recommend ascertainment of cardiac amyloidosis in individuals with increased wall thickness with either heart failure, aortic stenosis, or red flag signs/symptoms, particularly if older than 65 years (Figure 3).

Diagnostic algorithm

Once cardiac amyloidosis is suspected, a timely, definitive diagnosis should be obtained as patient outcomes depend largely on early initiation of therapy (particularly in AL).

As the large majority of cases of cardiac amyloidosis are AL and ATTR, we propose a diagnostic algorithm focusing on identifying these subtypes by the initial use of ^{99m}Tc-PYP, DPD or HMDP scintigraphy coupled to assessment for monoclonal proteins by SPIE, UPIE, and quantification of serum FLC (Figure 4).

The results of these tests could lead to four scenarios:

- (1) *Scintigraphy does not show cardiac uptake and assessments for monoclonal proteins are negative.* There is a very low probability of cardiac amyloidosis and ATTR and AL amyloidosis are unlikely. An alternative diagnosis should be considered. Nevertheless, if suspicion

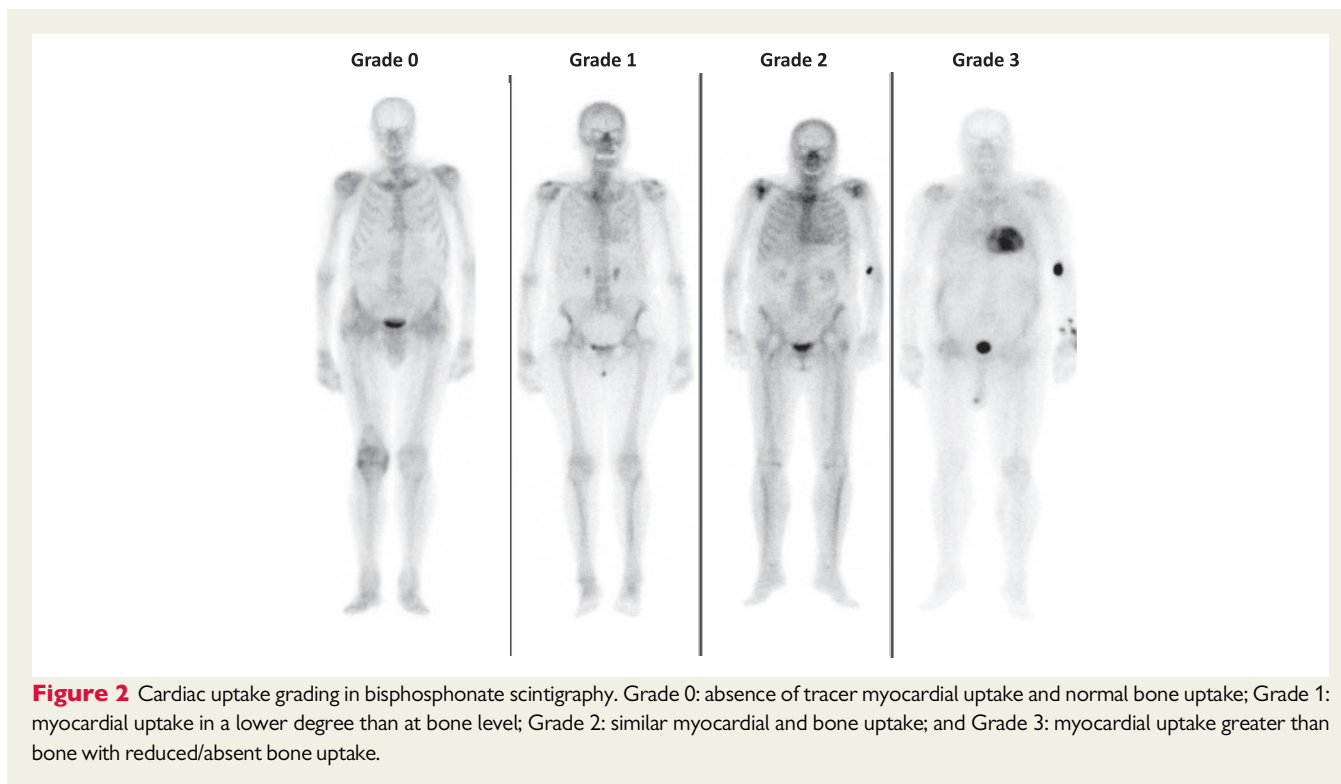


Figure 2 Cardiac uptake grading in bisphosphonate scintigraphy. Grade 0: absence of tracer myocardial uptake and normal bone uptake; Grade 1: myocardial uptake in a lower degree than at bone level; Grade 2: similar myocardial and bone uptake; and Grade 3: myocardial uptake greater than bone with reduced/absent bone uptake.

persists, consider CMR followed by cardiac or extracardiac biopsy as bone scintigraphy could be negative in some ATTRv mutations (tracer uptake depends on TTR fibril composition) and in rare subtypes of cardiac amyloidosis (Table 5).

- (2) *Scintigraphy shows cardiac uptake and assessments for monoclonal proteins are negative.* If cardiac uptake is Grade 2 or 3, ATTR cardiac amyloidosis can be diagnosed. Proceed with genetic testing to differentiate between ATTRv and ATTRwt forms. In the case that cardiac uptake is Grade 1, non-invasive diagnosis is not possible and histological confirmation of amyloid deposits (could be extracardiac) is required.
- (3) *Scintigraphy does not show cardiac uptake and at least one of the monoclonal protein tests is abnormal.* Light-chain amyloidosis has to be ruled out promptly and CMR can be used to confirm cardiac involvement. If CMR findings do not support cardiac amyloidosis, the diagnosis is very unlikely. In the case that CMR findings are supportive or inconclusive, cardiac or extracardiac histological demonstration of amyloid deposits is required to diagnose AL cardiac amyloidosis. Cardiac or other clinically affected organ biopsy is recommended to avoid time delay to diagnosis and consultation with a haematologist is warranted.¹⁴ If CMR cannot be performed promptly, consider performing biopsy directly.
- (4) *Scintigraphy shows cardiac uptake and at least one of the monoclonal protein tests is abnormal.* Transthyretin amyloidosis with concomitant MGUS (or any haematological disorder that produces FLC), AL amyloidosis, or coexistence of both AL and ATTR amyloidosis are possible in this scenario. Diagnosis of cardiac amyloidosis, in this case, requires histology with amyloid typing, usually via endomyocardial biopsy.

Essential concepts

- Cardiac amyloidosis should be considered in patients with increased wall thickness in the presence of cardiac or extracardiac red flags and/or in specific clinical situations.
- A diagnostic algorithm based initially on the use of bone scintigraphy coupled to assessment for monoclonal proteins allows appropriate diagnosis in patients with suggestive signs/symptoms.

Outcome and prognosis

Prognosis in cardiac amyloidosis

Although different methods to prognosticate in cardiac amyloidosis have been proposed, the focus has moved to multiparametric biomarker-based prognostic scores, and biomarker-based staging systems have been developed for AL and ATTR cardiac amyloidosis (Table 6).^{15–19}

Available scoring systems have been constructed using parameters obtained ‘at presentation’ and provide an initial prognostic stratification. The prognostic impact of any change of the scores during follow-up has not yet been validated, even though recent studies have shown promising results.²⁰

Progression of cardiac amyloidosis

While there have been multiple studies delineating baseline risk factors associated with adverse outcomes (principally mortality) in AL and ATTR, and data are emerging from the placebo arm of

Table 3 Serum and urine tests to rule out light-chain amyloidosis

Tests ^a	What does it detect?	Most sensitive test for:	Normal range
SPIE	Clonal immunoglobulin and/or clonal light chain	Confirming clonal immunoglobulin production	No monoclonal protein present
UPIE	Clonal immunoglobulin and/or clonal light chain	Confirming clonal light chain production	No monoclonal protein present
Serum free light-chain assay	Ratio of serum kappa: lambda light chains	Detecting low-level clonal light chain production; clonality assumed if ratio is far from 1:1	Freelite: 0.26–1.65 ^b N Latex: 0.53–1.51

eGFR, estimated glomerular filtration rate; SPIE, serum protein electrophoresis with immunofixation; UPIE, urine protein electrophoresis with immunofixation.

^aIf any of these tests are abnormal, bone scintigraphy should not be used to establish the diagnosis of transthyretin amyloidosis.

^bIn patients with kidney disease, mild elevations in the kappa: lambda ratio are frequently encountered. In the setting of a normal SPIE/UPIE, a kappa: lambda ratio up to 2.0 in subjects with eGFR ≤ 45 mL/min/1.73 m² (up to 3.1 if in dialysis) can typically be considered normal. This correction is not applicable to Siemens N Latex assay.

Table 4 Possible false positives and false negatives of bisphosphonate scintigraphy for detecting transthyretin cardiac amyloidosis

	Situation	How to suspect and confirm?
False positive	AL amyloidosis	Abnormal SPIE, UPIE or serum free light ratio. Requires histologic confirmation.
	Hydroxychloroquine cardiac toxicity	Interrogation. Requires histologic confirmation.
	AApoAI and AApoAll amyloidosis	Concomitant kidney disease present. Genetic testing.
	ApoAIV amyloidosis	Concomitant kidney disease present. Requires histologic confirmation.
	A β 2M amyloidosis	Long-term dialysis (>9 years). Requires histologic confirmation.
	Blood pool	Cardiac dysfunction could be present. Use SPECT to detect uptake in myocardium. Delay acquisition.
False negative	Rib fractures, valvular/annular calcifications	Use SPECT to detect uptake in myocardium.
	Recent myocardial infarction (<4 weeks)	Interrogation. Use SPECT to detect diffuse uptake in myocardium.
	Phe84Leu ATTRv, Ser97Tyr ATTRv	Concomitant neuropathy. Familial disease. Genetic testing.
	Very mild disease	Requires histologic confirmation.
	Delayed acquisition	Shorter acquisition time interval.
	Premature acquisition	Prolong acquisition time interval.

AApoAI, apolipoprotein AI amyloidosis; AApoAll, apolipoprotein All amyloidosis; AApoAIV, apolipoprotein A-IV amyloidosis; A β 2M, β 2-microglobulin amyloidosis; AL, light-chain amyloidosis; ATTRv, hereditary transthyretin amyloidosis; SPECT, single photon emission computed tomography; SPIE, serum protein electrophoresis with immunofixation; UPIE, urine protein electrophoresis with immunofixation.

therapeutic trials,²¹ there is a dearth of published data on longitudinal aspects of disease progression and none that are population-based without referral and ascertainment biases. In the era of emerging effective therapies, this is a major unmet need.

Follow-up of patients with cardiac amyloidosis

Although no studies have yet addressed the optimal follow-up scheme in patients with cardiac amyloidosis, a common scheme consists of 6-month visits with electrocardiogram (ECG) and complete blood tests (including NT-proBNP and troponin) and yearly echocardiogram and 24-h Holter ECG. A summary of recommended follow-up tests can be found in *Table 7*.

Follow-up of mutation carriers and genetic counselling

Genetic testing is recommended for relatives of patients with an inheritable form of cardiac amyloidosis. Such testing should occur along

with genetic counselling of patients and their families. As all hereditary amyloidoses have an adult onset, genetic testing of minors is discouraged. Genetic testing could be offered during young adulthood if genetic information would seem useful to guide professional choices or for reproductive planning.

As age of onset, clinical penetrance, and progression depend upon the variant, assessment of penetrance in allele carriers is generally recommended to start ~ 10 years prior to the age of disease onset in affected members of the family (or other individuals with the same mutation), or as soon as symptoms compatible with amyloidosis develop (*Table 7*).²²

Essential concepts

- While several staging systems are available to facilitate prognosis, there are limited data on how to assess progression. In the era of emerging effective specific therapies, this is a major unmet need.
- Follow-up of patients with cardiac amyloidosis and mutation carriers should be conducted following a structured protocol.

Table 5 Cardiac and extracardiac amyloidosis red flags

Type	Red flag	Amyloidosis where it is most frequently found	
Extracardiac			
Clinical	Polyneuropathy	ATTRv, AL, AA, AGel	
	Dysautonomia	ATTR, AL	
	Skin bruising	AL	
	Skin discoloration	AApoAI	
	Cutis laxa	AGel	
	Macroglossia	AL	
	Deafness	ATTRwt	
	Bilateral carpal tunnel syndrome	ATTRv, ATTRwt	
	Ruptured biceps tendon	ATTRwt	
	Lumbar spinal stenosis	ATTRwt	
	Vitreous deposits	ATTRv	
	Corneal lattice dystrophy	AGel	
	Family history	ATTRv, AApoAI, AApoAll	
	Laboratory	Renal insufficiency	AL, AA, AApoAI, AApoAll, AApoAIV, A β 2M, AFib
		Proteinuria	AL, AA, AApoAI, AApoAll, AFib
	Cardiac		
Clinical	Hypotension or normotensive if previous hypertensive	ATTR, AL	
ECG	Pseudoinfarct pattern	All	
	Low/decreased QRS voltage to degree of LV thickness	All	
	AV conduction disease	All	
Laboratory	Disproportionally elevated NT-proBNP to degree of HF	All	
	Persisting elevated troponin levels	ATTR, AL	
Echocardiogram	Granular sparkling of myocardium	All	
	Increased right ventricular wall thickness	All	
	Increased valve thickness	All	
	Pericardial effusion	All	
	Reduced longitudinal strain with apical sparing pattern	All	
CMR	Subendocardial late gadolinium enhancement	All	
	Elevated native T1 values	All	
	Increased extracellular volume	All	
	Abnormal gadolinium kinetics	All	

AA, serum amyloid A amyloidosis; AApoAI, apolipoprotein AI amyloidosis; AApoAll, apolipoprotein All amyloidosis; AApoAIV, apolipoprotein A-IV amyloidosis; A β 2M, β 2-microglobulin amyloidosis; AFib, fibrinogen amyloidosis; AGel, gelsolin amyloidosis; AL, light-chain amyloidosis; ATTRv, hereditary transthyretin amyloidosis; ATTRwt, wild-type transthyretin amyloidosis; AV, atrio-ventricular; CMR, cardiac magnetic resonance; ECG, electrocardiogram; HF, heart failure; LV, left ventricular; NT-proBNP, N-terminal pro-B-type natriuretic peptide.

Treatment

Treatment of cardiac amyloidosis involves two areas: (i) treatment and prevention of complications and (ii) stopping or delaying amyloid deposition by specific treatment.

Treatment of complications and comorbidities

Supportive care of patients with cardiac amyloidosis encompasses different clinical aspects including treatment of heart failure, arrhythmias, conduction disturbances, thromboembolism, and concomitant presence of severe aortic stenosis (Figure 5).^{23–25}

Specific (disease-modifying) treatment

Treating the process of amyloid deposition should target the production of amyloid precursor protein or the assembly of amyloid fibrils.

Light-chain amyloidosis

Specific treatment in cardiac AL amyloidosis should be undertaken by multidisciplinary teams involving oncohaematology and cardiology specialists and, whenever possible, patients should be referred to specialized centres.²⁶

Patients with AL amyloidosis not only have a haematologic malignancy, but also their multiorgan involvement makes them particularly fragile and susceptible to treatment toxicity. Therapeutic approaches

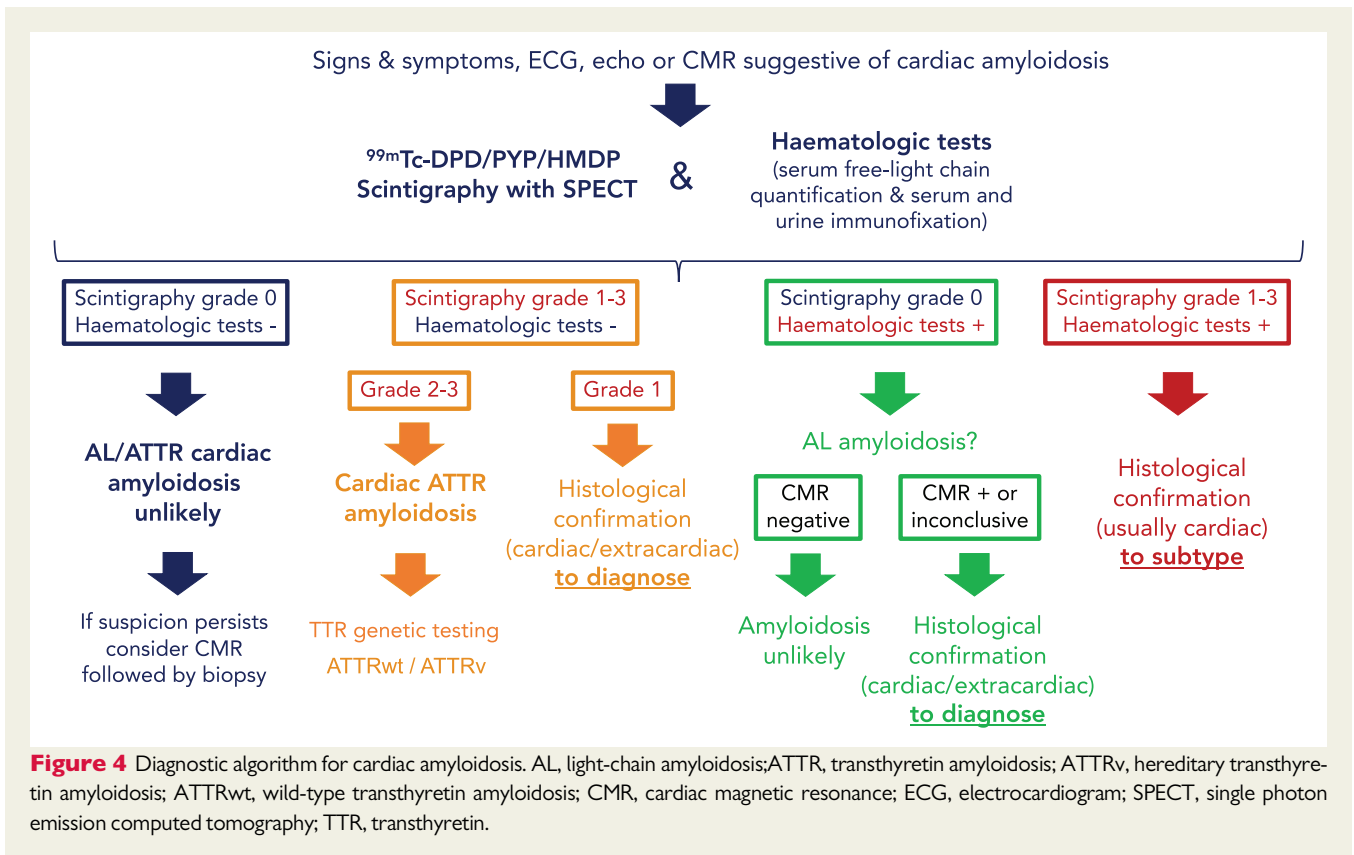
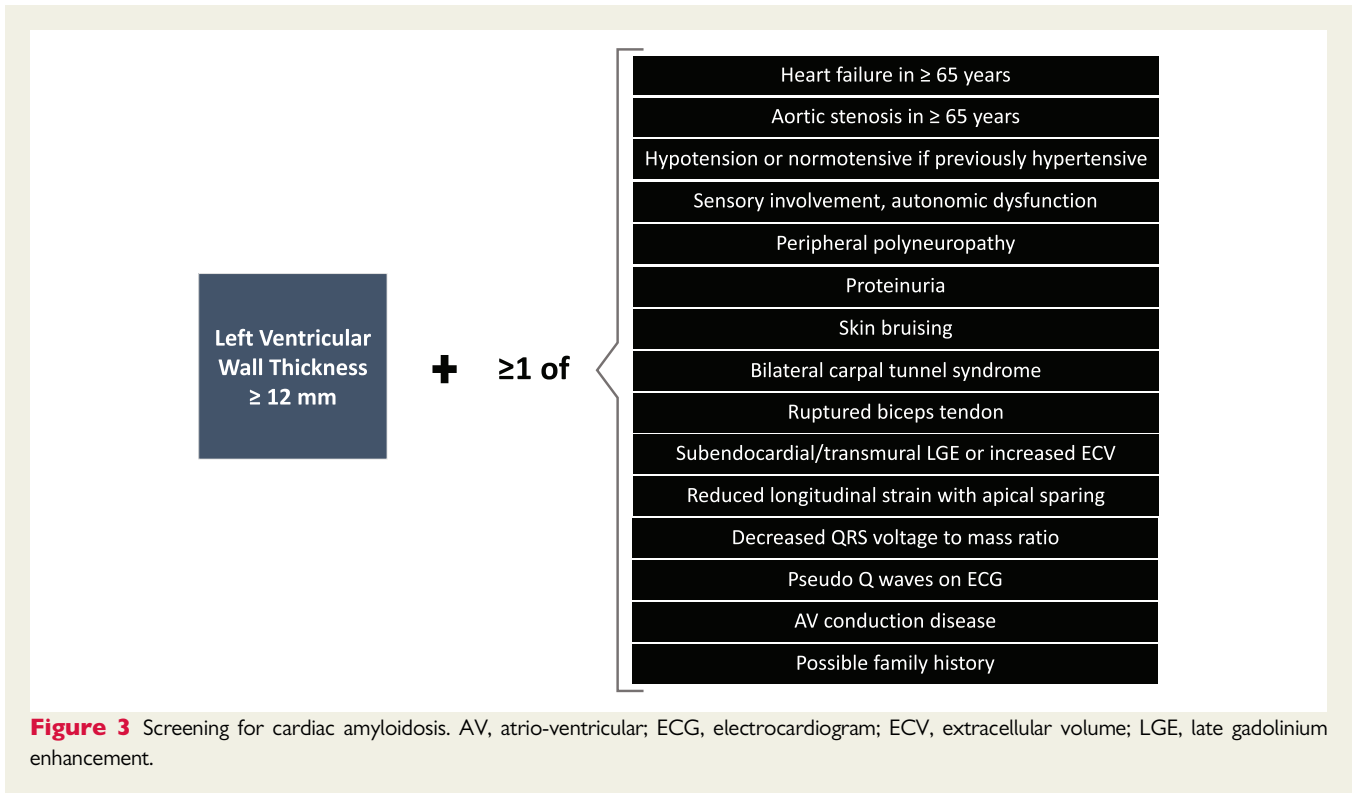


Table 7 Proposed follow-up scheme in cardiac amyloidosis

	AL	ATTR
Patients with cardiac amyloidosis	<p><i>Every month</i> (during initial haematological treatment):</p> <ul style="list-style-type: none"> • Complete blood count, basic biochemistry, NT-proBNP, and troponin • Serum free light chain quantification • Clinical evaluation by Haematology • Evaluation by Cardiology if clinically indicated <p><i>Every 3–4 months</i> (after completing initial haematological treatment):</p> <ul style="list-style-type: none"> • Complete blood count, basic biochemistry, NT-proBNP, and troponin • Serum free light chain quantification • Clinical evaluation by Haematology <p><i>Every 6 months:</i></p> <ul style="list-style-type: none"> • ECG • Echocardiography/CMR • Evaluation by Cardiology <p><i>Every 12 months:</i></p> <ul style="list-style-type: none"> • 24-h Holter ECG 	<p><i>Every 6 months:</i></p> <ul style="list-style-type: none"> • ECG • Blood tests including NT-proBNP and troponin • Neurological evaluation (if ATTRv) • 6MWD (optional) • KCCQ (optional) <p><i>Every 12 months:</i></p> <ul style="list-style-type: none"> • Echocardiography/CMR • 24-h Holter ECG • Ophthalmological evaluation (if ATTRv)
ATTRv asymptomatic genetic carriers^a		<p><i>Yearly:</i></p> <ul style="list-style-type: none"> • ECG • Blood tests including NT-proBNP and troponin • Echocardiography • Neurological and ophthalmological evaluation <p><i>Every 2 years:</i></p> <ul style="list-style-type: none"> • Holter ECG <p><i>Every 3 years or if any of above complementary tests is abnormal:</i></p> <ul style="list-style-type: none"> • Scintigraphy • CMR

6MWD, 6-min walking distance; AL, light-chain amyloidosis; ATTR, transthyretin amyloidosis; ATTRv, hereditary transthyretin amyloidosis; CMR, cardiac magnetic resonance; ECG, electrocardiogram; KCCQ, Kansas City Cardiomyopathy Questionnaire; NT-proBNP, N-terminal pro-B-type natriuretic peptide.

^aClinical follow-up to be started 10 years before the age of disease onset of affected relatives or predicted usual onset age for the specific ATTRv mutation.

depend on risk assessment that is defined in many circumstances by the degree of cardiac involvement (Supplementary material online, Figure S1) and cardiac response depends also on haematological response (Supplementary material online, Table S1).^{23,24} The role of the cardiologist in the specific treatment includes: (i) cardiac assessment for initial haematologic strategies, including consideration of autologous stem cell transplantation (Supplementary material online, Table S1), (ii) heart transplant evaluation, and (iii) cardiac monitoring during chemotherapy.

Transthyretin amyloidosis

There is an increasing availability of novel, effective, targeted therapeutic options for ATTRwt and ATTRv. A prompt diagnosis is essential to enable the timely treatment of neurological, cardiac, and other

systemic manifestations, as therapy is more effective in the early stages of the disease.^{27–29} Effective therapies reduce the production of mutated (liver transplantation) and overall TTR (genetic silencers) or stabilize circulating TTR molecule (stabilizers), preventing their dissociation or cleavage into amyloidogenic fragments (Figure 6). Several new compounds are under investigation, including agents directed to remove amyloid fibrils (Supplementary material online).

Current therapeutic alternatives distinguish between ATTRv and ATTRwt and, in the case of ATTRv, according to the presence of cardiomyopathy, polyneuropathy, or both (Figure 7). A detailed description of ATTR therapies that are either available or are being tested in phase III trials can be found in Supplementary material online. Tafamidis should be generally considered the agent of choice in ATTR cardiac patients with reasonable expected survival while

Treatment of Cardiac Complications and Comorbidities in Cardiac Amyloidosis

<h4>Aortic Stenosis</h4> <ul style="list-style-type: none"> • Severe AS confers worse prognosis. • Concomitant ATTRwt risk factor for periprocedural AV block. • TAVR improves outcome in amyloid-AS. 	<h4>Thromboembolism</h4> <ul style="list-style-type: none"> • High risk, common. • Anticoagulate if AF, consider in selected cases in SR. • Anticoagulate independent of CHADS-VASC score. 	<h4>Conduction disorders</h4> <ul style="list-style-type: none"> • PPM according to standard indications. • Consider CRT if high paced burden expected.
<h4>Heart failure</h4> <ul style="list-style-type: none"> • Control fluid. • Diuretics. • Deprescribe B-Blockers. • Avoid ACEI/ARB. • LVAD not suitable for most patients. • Heart transplant for selected cases. 	<h4>Atrial Fibrillation</h4> <ul style="list-style-type: none"> • Amiodarone, preferred AA. • Use digoxin cautiously. • Electrical CV has significant risk of complications and AF recurrence is frequent. • Exclude thrombi before electrical CV. • AF ablation data scarce and controversial. 	<h4>Ventricular arrhythmias</h4> <ul style="list-style-type: none"> • ICD for secondary prevention. • ICD in primary prevention usually not recommended. • Transvenous ICD preferred over subcutaneous ICD.

Figure 5 Treatment of cardiac complications and comorbidities in cardiac amyloidosis. AA, antiarrhythmic; ACEI, angiotensin-converting enzyme inhibitor; AF, atrial fibrillation; ARB, angiotensin receptor blocker; AS, aortic stenosis; ATTRwt, wild-type transthyretin amyloidosis; AV, atrio-ventricular; CRT, cardiac resynchronization therapy; CV, cardioversion; ICD, implantable cardioverter-defibrillator; LVAD, left ventricular assist device; PPM, permanent pacemaker; SR, sinus rhythm; TAVR, transcatheter aortic valve replacement.

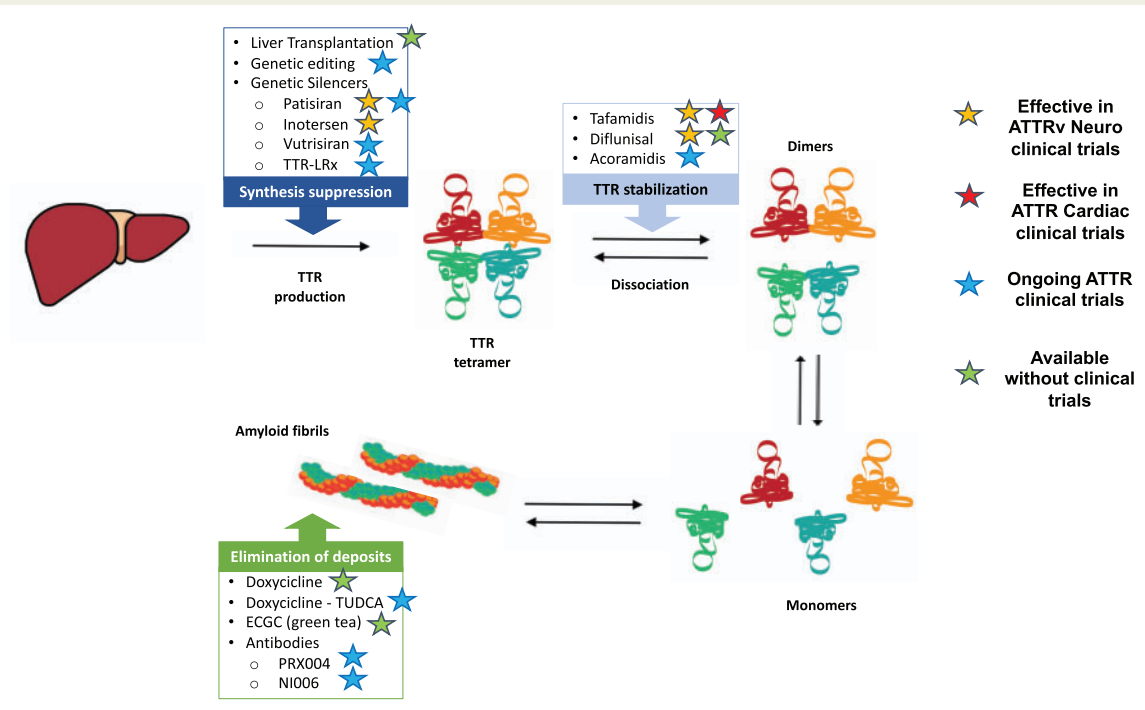


Figure 6 Available and future disease-modifying therapies in transthyretin amyloidosis (ATTR). ATTRv, hereditary transthyretin amyloidosis; TTR, transthyretin.

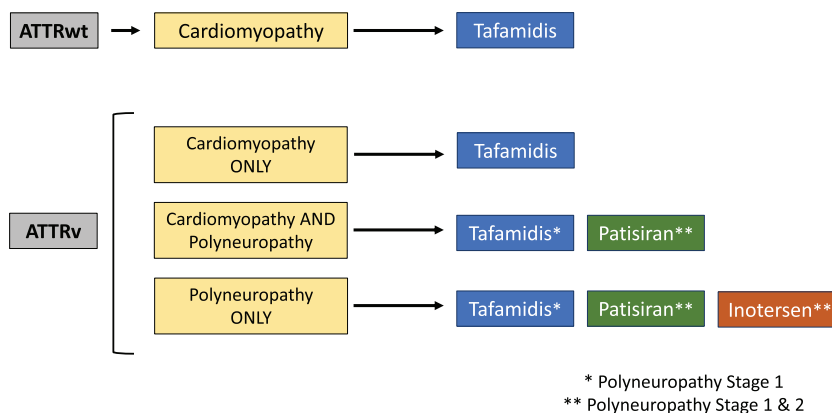


Figure 7 Proposed therapeutic alternatives in transthyretin amyloidosis patients. ATTRv, hereditary transthyretin amyloidosis; ATTRwt, wild-type transthyretin amyloidosis.

Table 8 Areas of investigation and uncertainty in cardiac amyloidosis

Pathophysiology

Amyloidogenesis

- Mechanism for tissue tropism
- Role of enzymatic cleavage
- Role of mechanical stress at tissue level

Determinants of phenotypic heterogeneity

- Gender
- Modifier genes
- Epigenetics
- Fibre composition

Diagnosis

Populations to screen for cardiac amyloidosis and optimal screening method

Expanded genetic testing in the overall population

Identification of a plasmatic biomarkers of unfolded TTR

Artificial intelligence tools to facilitate diagnosis (imaging, ECG, etc.)

Identification of the target of bone tracers within amyloid deposits

Validation of PET tracers for diagnosis of cardiac amyloidosis, differential diagnosis of ATTR vs. AL, and evaluation of amyloid burden

Natural history

Disease trajectories among carriers of different mutations

Definition and measurement of disease progression

- Ventricular thickness, mass, function
- Exercise capacity
- Biomarkers including monitoring of pre-albumin.
- TTR stability, kinetics, ligands as monitors of disease progression

Treatment of complications

Initiation of anticoagulation in patients without atrial fibrillation

Efficacy of heart failure drugs in patients with different degrees of heart failure

Efficacy of beta-blockers. Identification of patients who could benefit

Role of invasive heart failure monitoring devices

Identification of patients that benefit from prophylactic pacemaker

Identification of subgroups that can benefit from ICD and CRT

Continued

Disease-modifying treatments

- New antiplasma cell therapy in AL
- New stabilizers in ATTR
- New gene silencers in ATTR
- Early initiation of therapy:
 - ATTRv mutation carriers without phenotype
 - ATTR cardiac amyloidosis without heart failure
- Comparison between diverse disease-modifying drugs in ATTR
- Definition of disease progression despite therapy in ATTR
- Criteria for switching from one drug to another
- Early identification of responders/non-responders to specific therapies
- Role of combined therapy
- Antibodies to induce removal of tissue amyloid deposits
- Genetic editing treatments

AL, light-chain amyloidosis; ATTR, transthyretin amyloidosis; ATTRv, hereditary transthyretin amyloidosis; ATTRwt, wild-type transthyretin amyloidosis; CRT, cardiac resynchronization therapy; ECG, electrocardiogram; ICD, implantable cardioverter-defibrillator; PET, positron emission tomography; TTR, transthyretin.

patirsiran could be considered in ATTRv patients with cardiac involvement in whom gene silencers are prescribed due to symptomatic neurological disease.

Essential concepts

- Management of cardiac amyloidosis involves treatment and prevention of complications, and halting or delaying amyloid deposition by specific treatments.
- Specific pharmacologic treatments available for ATTR amyloidosis include stabilizing molecules (tafamidis) and genetic silencers (patirsiran and inotersen).
- Tafamidis is currently the only drug that has shown efficacy in a randomized trial in patients with ATTRwt and ATTRv with cardiomyopathy, and should be considered in patients with reasonable expected survival.

Organization of patient care

Collaboration between centres remains essential because not all centres can perform complex diagnostic techniques (such as endomyocardial biopsy and mass spectrometry) or prescribe disease-modifying therapies, and interaction between cardiologists, haematologists, transplant surgeons, neurologists, and other specialists could be needed. The best strategy for the management of patients with amyloidosis is not the 'hub-and-spoke' model, but rather a network where centres can do at least some parts of the diagnostic workup, exchange opinions and information, and refer patients to regional or national referral centres for selected procedures or particularly complex decisions.

Summary and future directions

As knowledge evolves and new therapeutic alternatives to treat cardiac amyloidosis emerge, new areas of research and unsolved questions arise. Some of the grey zones and areas of active research are summarized in *Table 8*.

It is expected that advances in the field will change the way we diagnose, prognosticate, and treat cardiac amyloidosis in the next few years. Meanwhile, in this paper, the ESC Working Group on Myocardial and Pericardial Diseases proposes an invasive and non-invasive definition of cardiac amyloidosis, addresses clinical scenarios and situations to suspect the condition, and proposes a diagnostic algorithm to aid diagnosis. Furthermore, we also review how to monitor and treat cardiac amyloidosis, in an attempt to bridge the gap between the latest advances in the field and clinical practice.

Supplementary material

Supplementary material is available at *European Heart Journal* online.

Funding

P.G.-P. reports grant support from Instituto de Salud Carlos III (PI20/01379). M.F. is supported by a British Heart Foundation Intermediate Clinical Research Fellowship (FS/18/21/33447). E.G.-L. reports grant support from Instituto de Salud Carlos III (PI18/0765). M.S.M. reports grant support from National Institutes of Health [R01HL139671-01], [R21AG058348], and [K24AG036778].

Conflict of interest: M.A. reports receiving an Advisory board fee and a Research Grant from Pfizer and from Sanofi Genzyme. U.E. reports consulting fees and grant support from Pfizer and Sanofi. Institutional grants from Pfizer. M.F. reports consulting fees from Pfizer, Akcea, Ionis, Alnylam, Alexion, Sanofi, and research grant from Pfizer. P.G.P. reports speaking fees from Pfizer, Eidos, Alnylam, and Akcea. Consulting fees from Pfizer, Eidos, Neuroimmune, Alnylam, Prothena, and Akcea. Research support to his institution from Pfizer, Eidos, and Alnylam. J.D.G. reports consulting and speaking fees from Pfizer, Akcea, Alnylam, and Eidos. E.G.-L. reports speaking fees from Pfizer and Alnylam. Consulting fees from Pfizer and Proclara. Research support to her institution from Pfizer, Eidos, and Alnylam. M.G. reports grant/clinical trial support from Alnylam, Eidos, Prothena, and Pfizer. I.K. reports speaking fees from Akcea Therapeutics Germany and Pfizer and consulting fees from Akcea

Therapeutics Germany. A.V.K. reports consulting fees from Pfizer, Akcea, Alnylam, and Neurimmune as well as speaking fees from Pfizer, Akcea, and Alnylam. A.L. reports speaking fees from Pfizer. Consulting fees from Pfizer and Alnylam. M.S.M. reports consulting income from Pfizer, GSK, Eldos, Prothena, Akcea, and Alnylam, and institution received clinical trial funding from Pfizer, Prothena, Eidos, and Alnylam. C.R. reports speaking fees from Pfizer, Alnylam, and Akcea. Consulting fees from Pfizer, Alnylam, Prothena, and Akcea. Institutional Research Grants from Pfizer. A.G.R. reports honoraria for presentations from Astra-Zeneca. Other authors declare no conflict of interest.

References

- Maurer MS, Elliott P, Comenzo R, Semigran M, Rapezzi C. Addressing common questions encountered in the diagnosis and management of cardiac amyloidosis. *Circulation* 2017;**135**:1357–1377.
- Ruberg FL, Grogan M, Hanna M, Kelly JW, Maurer MS. Transthyretin amyloid cardiomyopathy: JACC state-of-the-art review. *J Am Coll Cardiol* 2019;**73**:2872–2891.
- Benson MD, Buxbaum JN, Eisenberg DS, Merlini G, Saraiva MJM, Sekijima Y, Sipe JD, Westermarck P. Amyloid nomenclature 2018: recommendations by the International Society of Amyloidosis (ISA) nomenclature committee. *Amyloid* 2018;**25**:215–219.
- Maleszewski JJ. Cardiac amyloidosis: pathology, nomenclature, and typing. *Cardiovasc Pathol* 2015;**24**:343–350.
- Boldrini M, Cappelli F, Chacko L, Restrepo-Cordoba MA, Lopez-Sainz A, Giannoni A, Aimo A, Baggiano A, Martinez-Naharro A, Whelan C, Quarta C, Passino C, Castiglione V, Chubuchnyi V, Spini V, Taddei C, Vergaro G, Petrie A, Ruiz-Guerrero L, Moñivas V, Mingo-Santos S, Mirelis JG, Dominguez F, Gonzalez-Lopez E, Perlini S, Pontone G, Gillmore J, Hawkins PN, Garcia-Pavia P, Emdin M, Fontana M. Multiparametric echocardiography scores for the diagnosis of cardiac amyloidosis. *JACC Cardiovasc Imaging* 2020;**13**:909–920.
- Gillmore JD, Maurer MS, Falk RH, Merlini G, Damy T, Dispenzieri A, Wechalekar AD, Berk JL, Quarta CC, Grogan M, Lachmann HJ, Bokhari S, Castano A, Dorbala S, Johnson GB, Glaudemans AW, Rezk T, Fontana M, Palladini G, Milani P, Guidalotti PL, Flatman K, Lane T, Vonberg FW, Whelan CJ, Moon JC, Ruberg FL, Miller EJ, Hutt DF, Hazenberg BP, Rapezzi C, Hawkins PN. Nonbiopsy diagnosis of cardiac transthyretin amyloidosis. *Circulation* 2016;**133**:2404–2412.
- Palladini G, Russo P, Bosoni T, Verga L, Sarais G, Lavatelli F, Nuvoletone M, Obici L, Casarini S, Donadei S, Albertini R, Righetti G, Marini M, Graziani MS, Melzi D'Eril GV, Moratti R, Merlini G. Identification of amyloidogenic light chains requires the combination of serum-free light chain assay with immunofixation of serum and urine. *Clin Chem* 2009;**55**:499–504.
- Sprangers B, Claes K, Evenepoel P, Kuypers D, Poesen K, Delforge M, Bossuyt VX, Meijers B. Comparison of 2 serum-free light-chain assays in CKD patients. *Kidney Int Rep* 2020;**5**:627–631.
- Layoun ME, Desmarais J, Heitner SB, Masri A. Hot hearts on bone scintigraphy are not all amyloidosis: hydroxychloroquine-induced restrictive cardiomyopathy. *Eur Heart J* 2020;**41**:2414–2414.
- López-Sainz Á, Hernandez-Hernandez A, Gonzalez-Lopez E, Domínguez F, Restrepo-Cordoba MA, Cobo-Marcos M, Gómez-Bueno M, Hernandez-Perez FJ, Oteo JF, Mirelis JG, Caverio MA, Moñivas V, Mingo SS, de Haro-Del Moral FJ, Krsnik I, Salas C, Bornstein B, Briceño A, López JA, Vázquez J, Alonso-Pulpón L, Segovia J, Garcia-Pavia P. Clinical profile and outcome of cardiac amyloidosis in a Spanish referral center. *Rev Esp Cardiol (Engl Ed)* 2021;**74**:149–158.
- González-López E, Gallego-Delgado M, Guzzo-Merello G, de Haro-Del Moral FJ, Cobo-Marcos M, Robles C, Bornstein B, Salas C, Lara-Pezzi E, Alonso-Pulpón L, Garcia-Pavia P. Wild-type transthyretin amyloidosis as a cause of heart failure with preserved ejection fraction. *Eur Heart J* 2015;**36**:2585–2594.
- Damy T, Costes B, Hagege AA, Donal E, Eicher JC, Slama M, Guellich A, Rappeneau S, Gueffet JP, Logeart D, Planté-Bordeneuve V, Bouvaist H, Huttin O, Mulak G, Dubois-Randé JL, Goossens M, Canoui-Poitrine F, Buxbaum JN. Prevalence and clinical phenotype of hereditary transthyretin amyloid cardiomyopathy in patients with increased left ventricular wall thickness. *Eur Heart J* 2016;**37**:1826–1834.
- Castaño A, Narotsky DL, Hamid N, Khaliq OK, Morgenstern R, DeLuca A, Rubin J, Chiuzan C, Nazif T, Vahl T, George I, Kodali S, Leon MB, Hahn R, Bokhari S, Maurer MS. Unveiling transthyretin cardiac amyloidosis and its predictors among elderly patients with severe aortic stenosis undergoing transcatheter aortic valve replacement. *Eur Heart J* 2017;**38**:2879–2887.
- Sayago I, Krsnik I, Gómez-Bueno M, García-Pavía P, Jaramillo N, Salas C, Mingo S, Oteo JF, Alonso-Pulpón L, Segovia J. Analysis of diagnostic and therapeutic strategies in advanced cardiac light-chain amyloidosis. *J Heart Lung Transplant* 2016;**35**:995–1002.
- Kumar S, Dispenzieri A, Lacy MQ, Hayman SR, Buadi FK, Colby C, Laumann K, Zeldenrust SR, Leung N, Dingli D, Greipp PR, Lust JA, Russell SJ, Kyle RA, Rajkumar SV, Gertz MA. Revised prognostic staging system for light chain amyloidosis incorporating cardiac biomarkers and serum free light chain measurements. *J Clin Oncol* 2012;**30**:989–995.
- Lillenes B, Ruberg FL, Mussinelli R, Doros G, Sancharawala V. Development and validation of a survival staging system incorporating BNP in patients with light chain amyloidosis. *Blood* 2019;**133**:215–223.
- Grogan M, Scott CG, Kyle RA, Zeldenrust SR, Gertz MA, Lin G, Klarich KW, Miller WL, Maleszewski JJ, Dispenzieri A. Natural history of wild-type transthyretin cardiac amyloidosis and risk stratification using a novel staging system. *J Am Coll Cardiol* 2016;**68**:1014–1020.
- Gillmore JD, Damy T, Fontana M, Hutchinson M, Lachmann HJ, Martinez-Naharro A, Quarta CC, Rezk T, Whelan CJ, Gonzalez-Lopez E, Lane T, Gilbertson JA, Rowczenio D, Petrie A, Hawkins PN. A new staging system for cardiac transthyretin amyloidosis. *Eur Heart J* 2018;**39**:2799–2806.
- Cheng RK, Levy WC, Vasbinder A, Teruya S, De Los Santos J, Leedy D, Maurer MS. Diuretic dose and NYHA functional class are independent predictors of mortality in patients with transthyretin cardiac amyloidosis. *JACC CardioOncol* 2020;**2**:414–424.
- Law S, Petrie A, Chacko L, Cohen OC, Ravichandran S, Gilbertson JA, Rowczenio D, Wechalekar A, Martinez-Naharro A, Lachmann HJ, Whelan CJ, Hutt DF, Hawkins PN, Fontana M, Gillmore JD. Disease progression in cardiac transthyretin amyloidosis is indicated by serial calculation of National Amyloidosis Centre transthyretin amyloidosis stage. *ESC Heart Fail* 2020;**7**:3942–3949.
- Maurer MS, Schwartz JH, Gundapaneni B, Elliott PM, Merlini G, Waddington-Cruz M, Kristen AV, Grogan M, Witteles R, Damy T, Drachman BM, Shah SJ, Hanna M, Judge DP, Barsdorf AI, Huber P, Patterson TA, Riley S, Schumacher J, Stewart M, Sultan MB, Rapezzi C, ATTR-ACT Study Investigators. Tafamidis treatment for patients with transthyretin amyloid cardiomyopathy. *N Engl J Med* 2018;**379**:1007–1016.
- Conceição I, Coelho T, Rapezzi C, Parman Y, Obici L, Galán L, Rousseau A. Assessment of patients with hereditary transthyretin amyloidosis—understanding the impact of management and disease progression. *Amyloid* 2019;**26**:103–111.
- Muchtar E, Grace L, Grogan M. The challenges in chemotherapy and stem cell transplantation for light-chain amyloidosis. *Can J Cardiol* 2020;**36**:384–395.
- Saith SE, Maurer MS, Patel AR. Systemic amyloidosis due to monoclonal immunoglobulins. *Hematol Oncol Clin North Am* 2020;**34**:1055–1068.
- Garcia-Pavia P, Domínguez F, Gonzalez-Lopez E. Transthyretin amyloid cardiomyopathy. *Med Clin (Barc)* 2021;**156**:126–134.
- Palladini G, Merlini G. What is new in diagnosis and management of light chain amyloidosis? *Blood* 2016;**128**:159–168.
- Rapezzi C, Elliott P, Damy T, Nativi-Nicolau J, Berk JL, Velazquez EJ, Boman K, Gundapaneni B, Patterson TA, Schwartz JH, Sultan MB, Maurer MS. Efficacy of tafamidis in patients with hereditary and wild-type transthyretin amyloid cardiomyopathy: further analyses from ATTR-ACT. *JACC Heart Fail* 2021;**9**:115–123.
- Adams D, Gonzalez-Duarte A, O'Riordan WD, Yang C-C, Ueda M, Kristen AV, Tournev I, Schmidt HH, Coelho T, Berk JL, Lin K-P, Vita G, Attarian S, Planté-Bordeneuve V, Mezei MM, Campistol JM, Buades J, Brannagan TH, Kim BJ, Oh J, Parman Y, Sekijima Y, Hawkins PN, Solomon SD, Polydefkis M, Dyck PJ, Gandhi PJ, Goyal S, Chen J, Strahs AL, Nochur SV, Sweetser MT, Garg PP, Vaishnav AK, Gollob JA, Suhr OB. Patisiran, an RNAi therapeutic, for hereditary transthyretin amyloidosis. *N Engl J Med* 2018;**379**:11–21.
- Benson MD, Waddington-Cruz M, Berk JL, Polydefkis M, Dyck PJ, Wang AK, Planté-Bordeneuve V, Barroso FA, Merlini G, Obici L, Scheinberg M, Brannagan TH 3rd, Litchy WJ, Whelan C, Drachman BM, Adams D, Heitner SB, Conceição I, Schmidt HH, Vita G, Campistol JM, Gamez J, Gorevic PD, Gane E, Shah AM, Solomon SD, Monia BP, Hughes SG, Kwoh TJ, McEvoy BW, Jung SW, Baker BF, Ackermann EJ, Gertz MA, Coelho T. Inotersen treatment for patients with hereditary transthyretin amyloidosis. *N Engl J Med* 2018;**379**:22–31.