

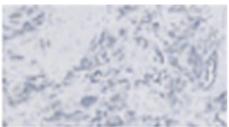
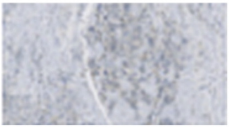
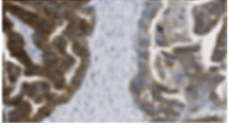
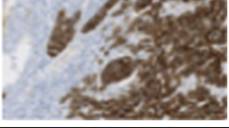
Clinical Diagnosis	IHC Score	Staining Criteria	Representative IHC Images
<b>Negative</b>	<b>0</b>	No or equivocal staining in tumor cells or < 50% tumor cells with membrane and/or cytoplasmic staining	
<b>Negative</b>	<b>1+</b>	≥ 50% tumor cells with weak or higher membrane and/or cytoplasmic staining but < 50% tumor cells with moderate or higher staining intensity	
<b>Positive</b>	<b>2+</b>	≥ 50% tumor cells with moderate or higher membrane and/or cytoplasmic staining but < 50% tumor cells with strong staining intensity	
<b>Positive</b>	<b>3+</b>	≥ 50% tumor cells with strong or higher membrane and/or cytoplasmic staining intensity	

Fig A1. MET immunohistochemistry (IHC) scoring criteria.